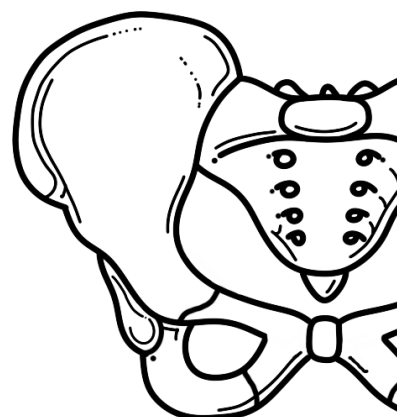
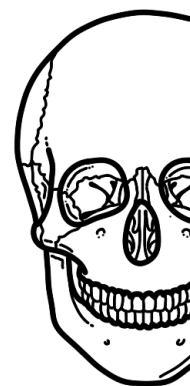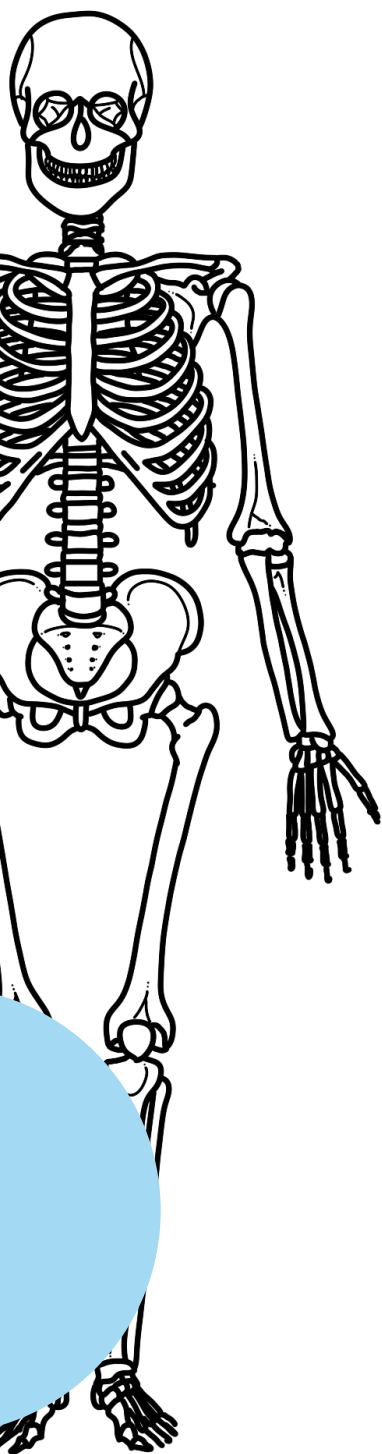


ANATOMIE KLEURBOEK

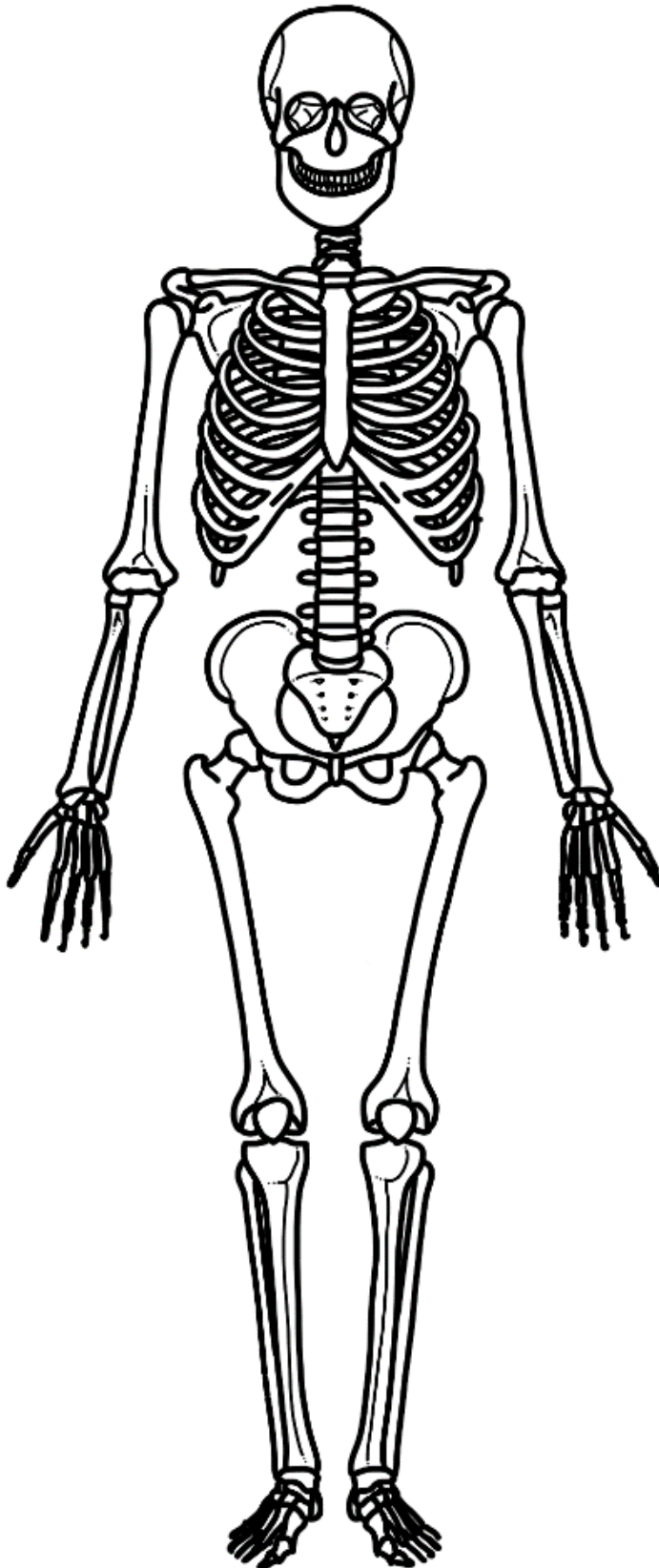
Belangrijkste botten in ons lichaam

Inhoudsopgave:

- p.1 Algemene anatomie
- p.2 Schedelbotten, wervelkolom
- p.3 Thorax en armen
- p.4 Pelvis en benen

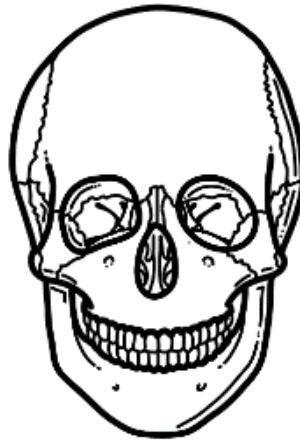
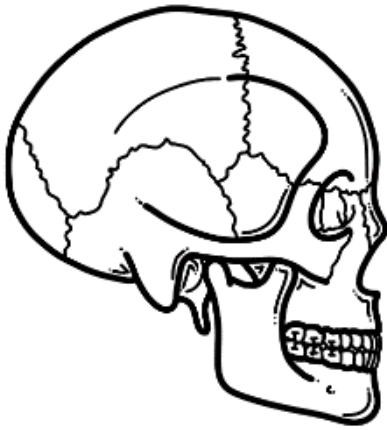

Algemene anatomie



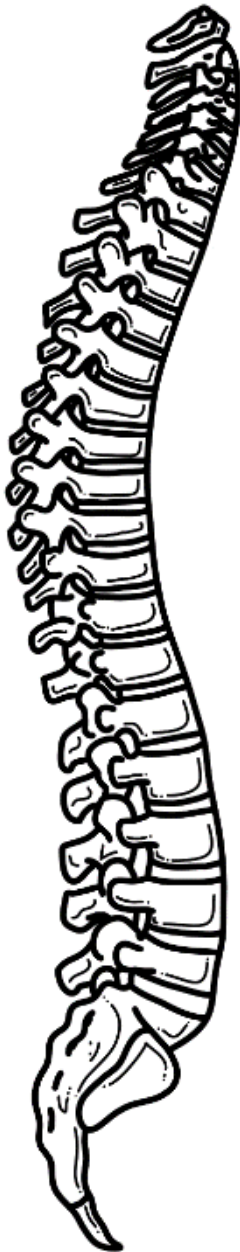- Cranium
- Orbita
- Mandibula
- Maxilla
- Ribben
- Sternum
- Clavicula
- Scapula
- Humerus
- Ulna
- Radius
- Ossa carpi
- Ossa metacarpi
- Phalanges (hand)
- Cervicale wervels
- Thoracale wervels
- Lumbale wervels
- Os sacrum
- Os coccygis
- Ossa coxae
- Femur
- Patella
- Fibula
- Tibia
- Ossa tarsi
- Ossa metatarsi
- Phalanges (voet)

Schedelbotten



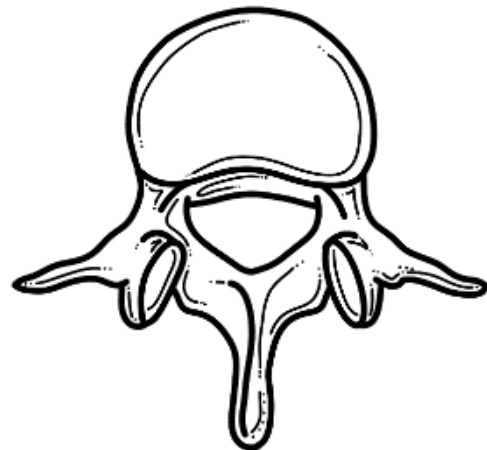
- Os frontale
- Os pariëtale
- Os temporale
- Os occipitale

Wervelkolom

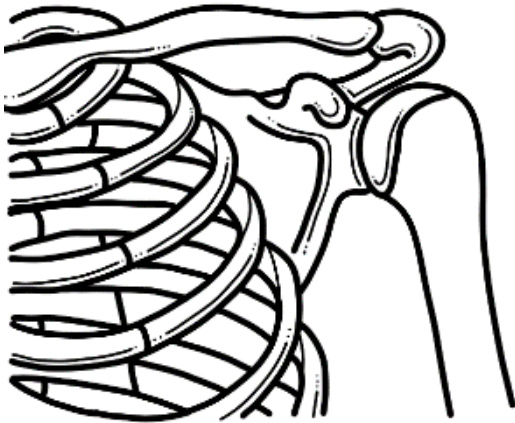


- Cervicale wervelkolom
- Thoracale wervelkolom
- Lumbale wervelkolom
- Os sacrum
- Os coccygis

- Corpus vertebrae
- Arcus vertebrae
- Processus spinosus
- Foramen vertebrale
(wat loopt hier?)

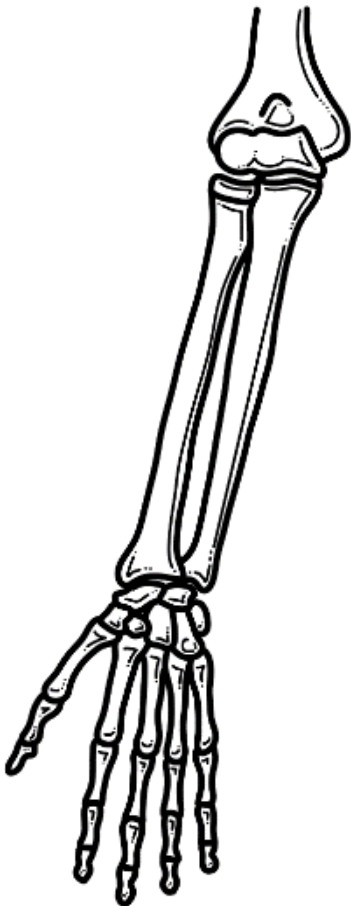


Thorax en armen



- | | | | |
|--------------------------|--------------------|--------------------------|-------------------|
| <input type="checkbox"/> | 1 ^e rib | <input type="checkbox"/> | Clavicula |
| <input type="checkbox"/> | 2 ^e rib | <input type="checkbox"/> | Scapula |
| <input type="checkbox"/> | 3 ^e rib | <input type="checkbox"/> | Acromion |
| <input type="checkbox"/> | 4 ^e rib | <input type="checkbox"/> | Proc. coraccideus |
| <input type="checkbox"/> | 5 ^e rib | <input type="checkbox"/> | Humerus |
| <input type="checkbox"/> | 6 ^e rib | | |

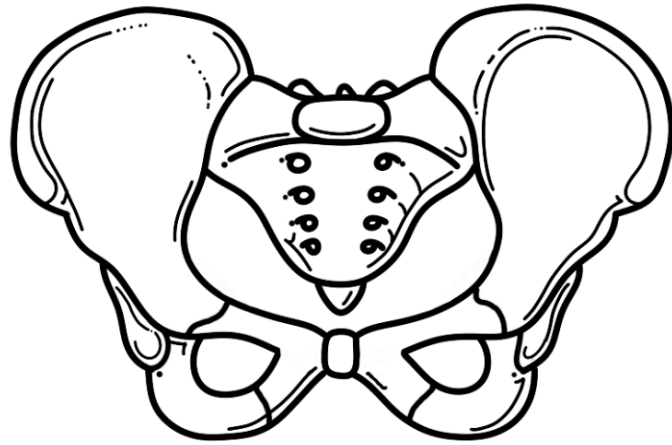
Rechter arm



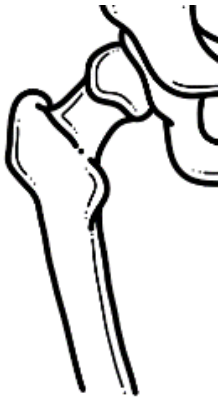- | | |
|--------------------------|--------------------|
| <input type="checkbox"/> | Humerus |
| <input type="checkbox"/> | Ulna |
| <input type="checkbox"/> | Radius |
| <input type="checkbox"/> | Ossa carpi |
| <input type="checkbox"/> | Ossa metacarpi |
| <input type="checkbox"/> | Phalanx proximalis |
| <input type="checkbox"/> | Phalanx media |
| <input type="checkbox"/> | Phalanx distalis |

Pelvis en benen

- Os sacrum
- Os coccygis
- Symfyse
- Spina iliaca anterior superior
- Os ilium
- Os ischii
- Os pubis



Rechter bovenbeen



- Bekken
- Collum femoris
- Trochanter major
- Trochanter minor
- Femur

Rechter onderbeen

- Femur
- Fibula
- Tibia
- Patella
- Ossa tarsi
- Ossa metatarsi
- Calcaneus
- Phalanx proximalis
- Phalanx media
- Phalanx distalis

